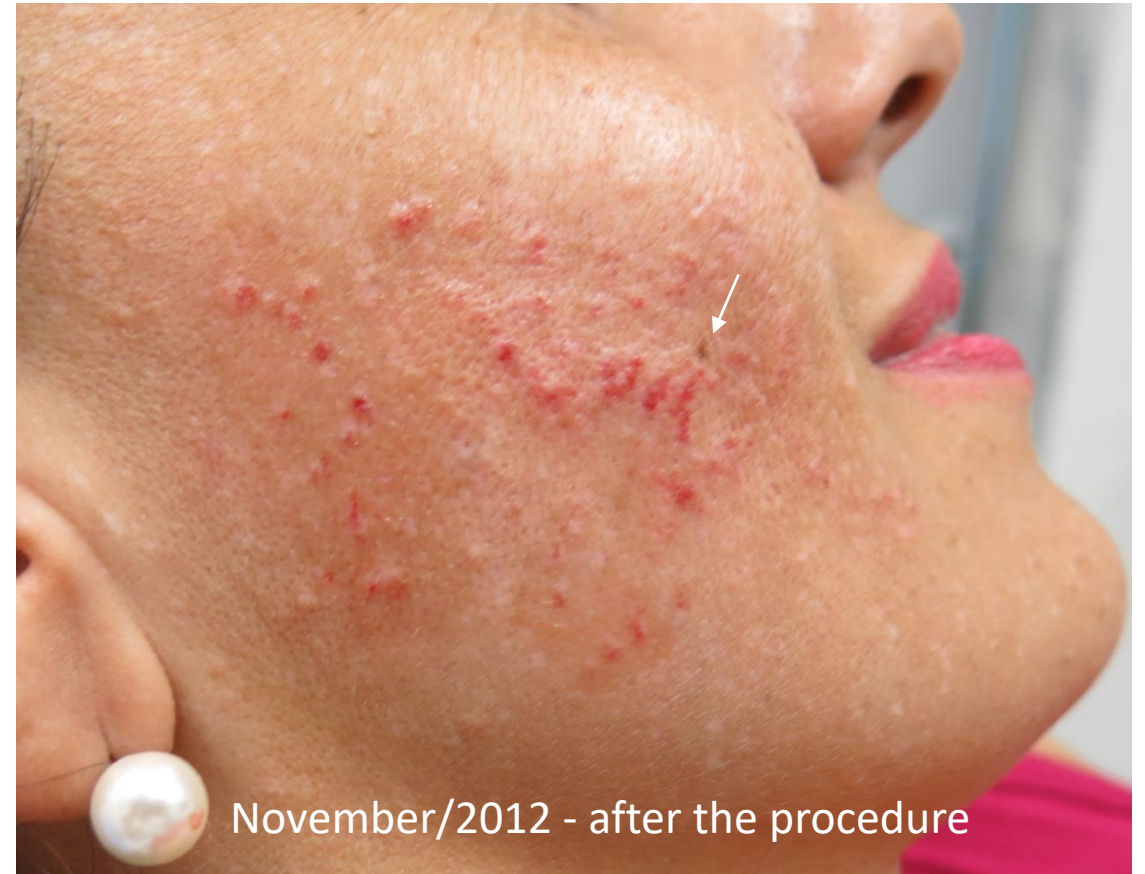
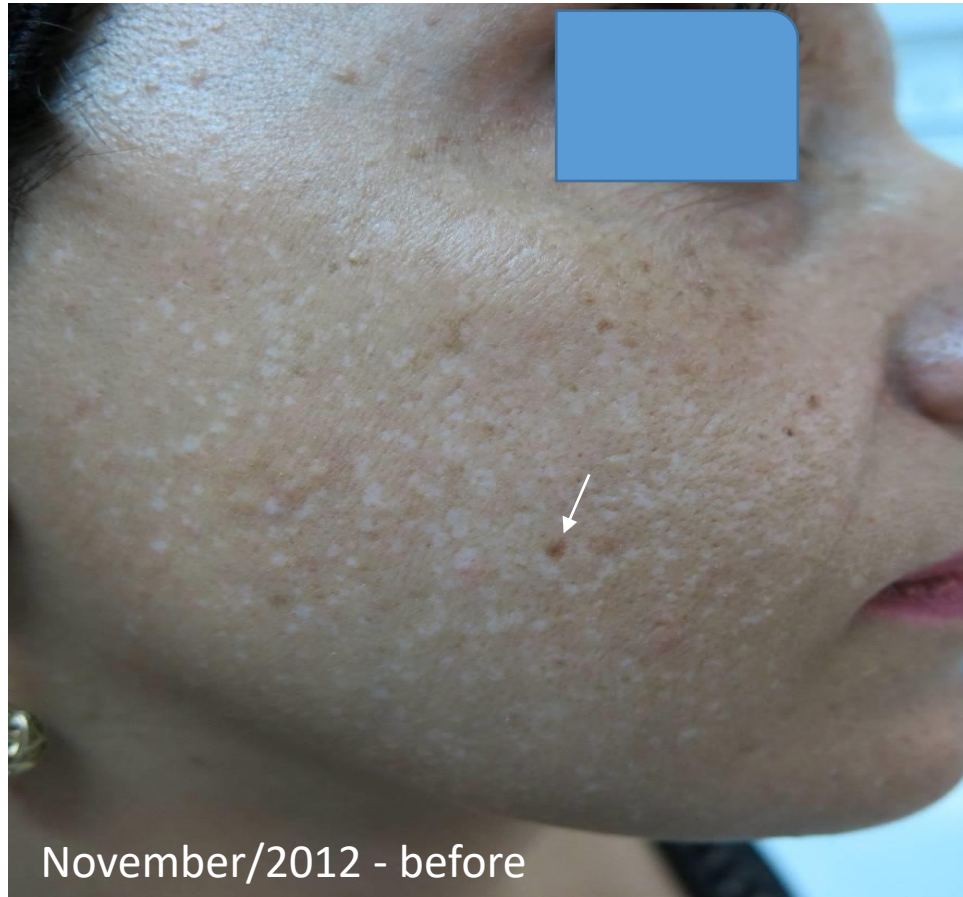
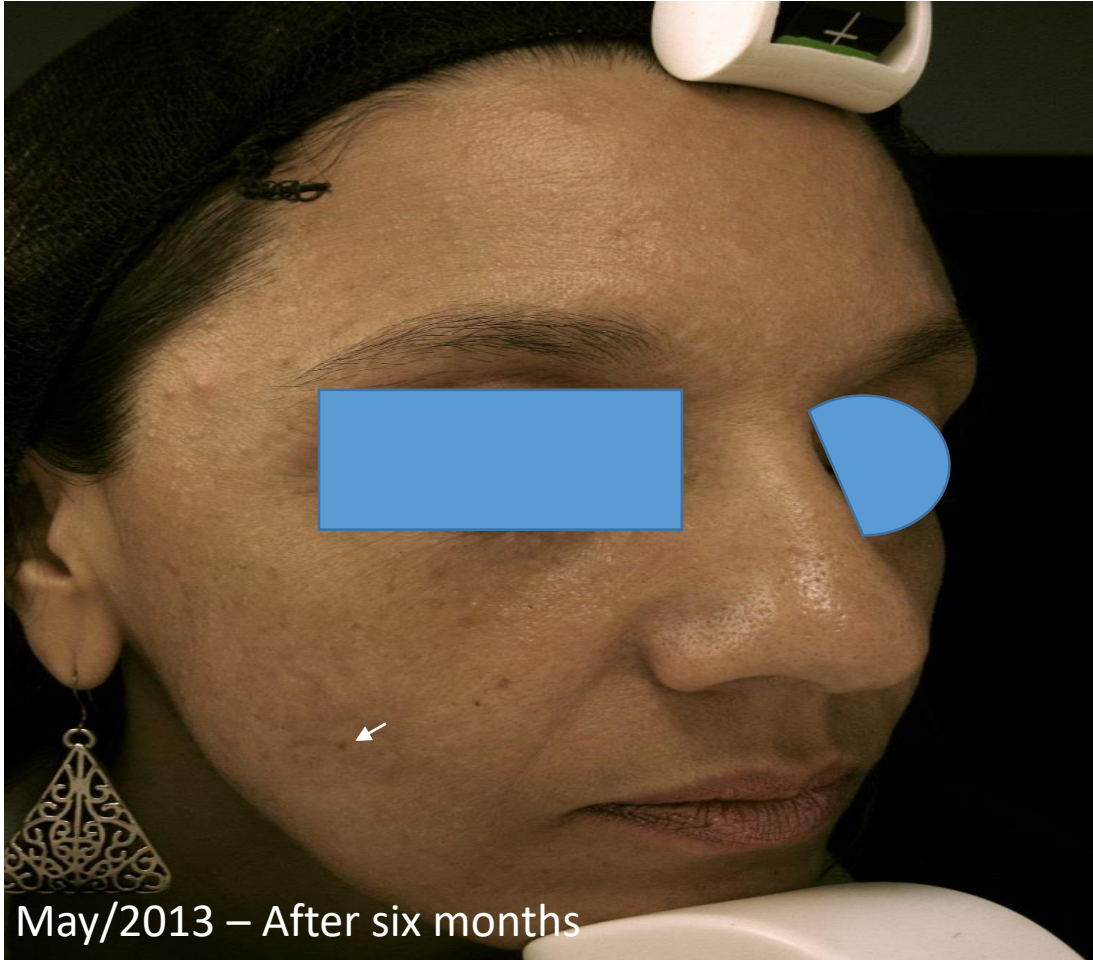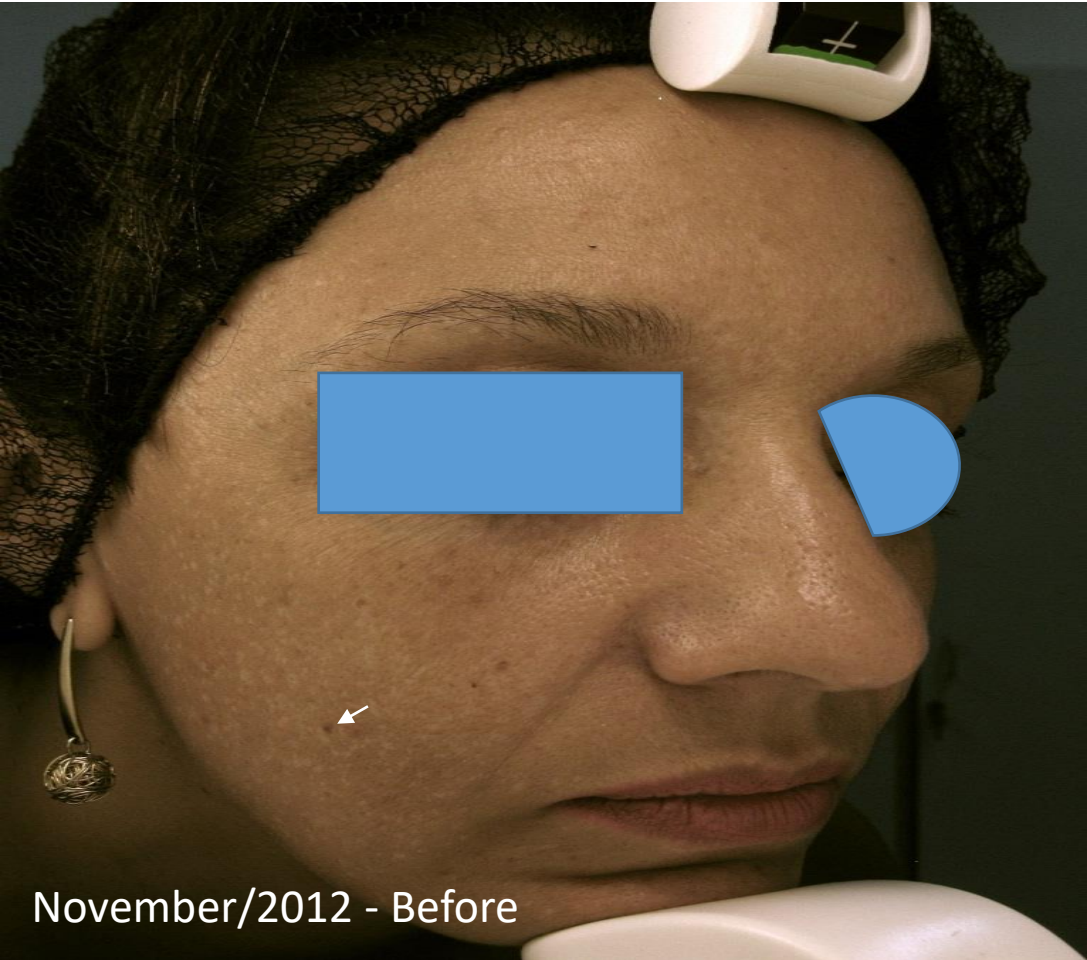Idiopathic guttate hypomelanosis (IGH) on the face, also called confetti leukoderma (for me, confetti leukoderma is a facial manifestation of IGH).

White arrow indicates a nevus (as a landmark).

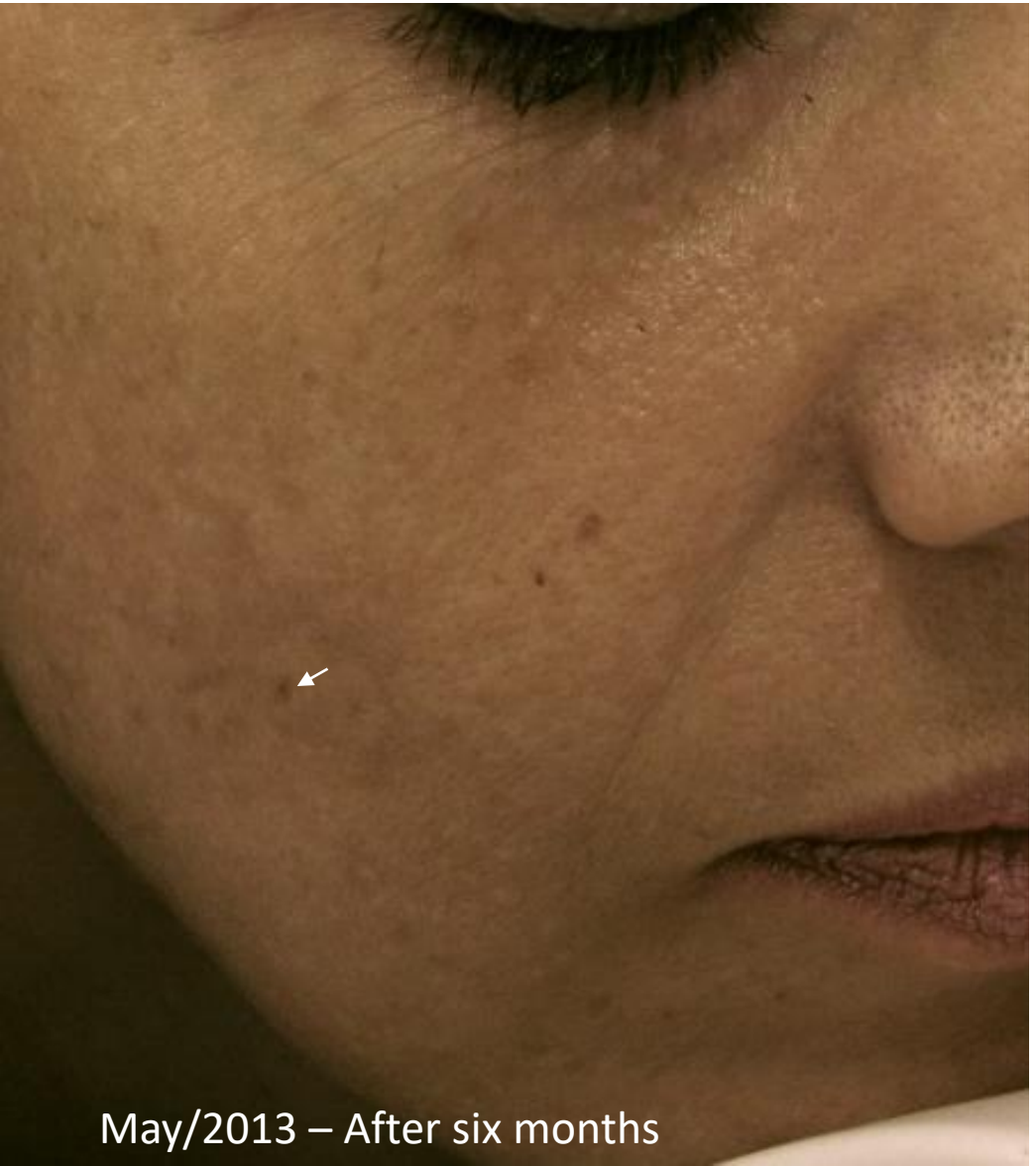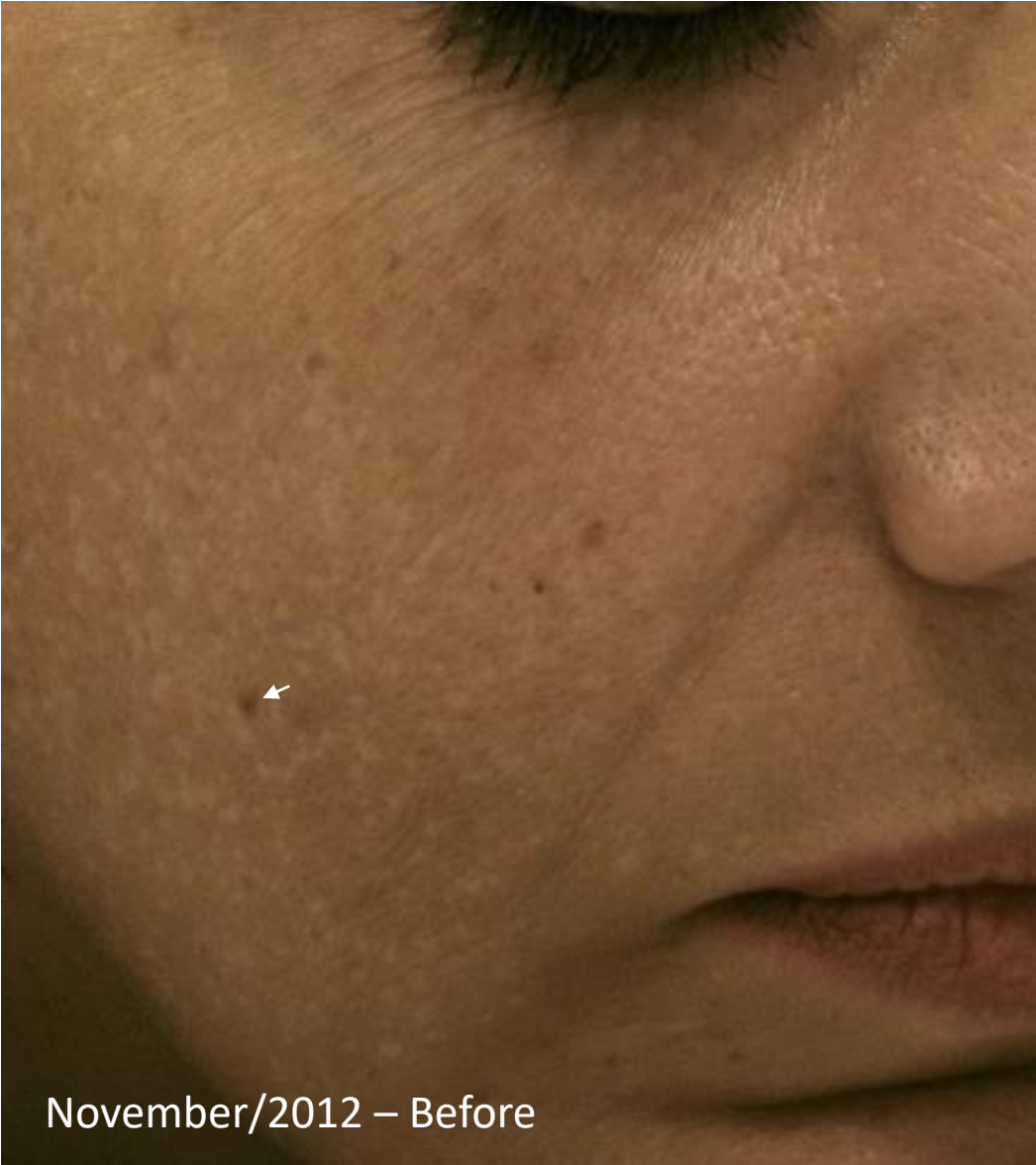Treatment performed with 5FU MMP near the nevic lesion in November/2012

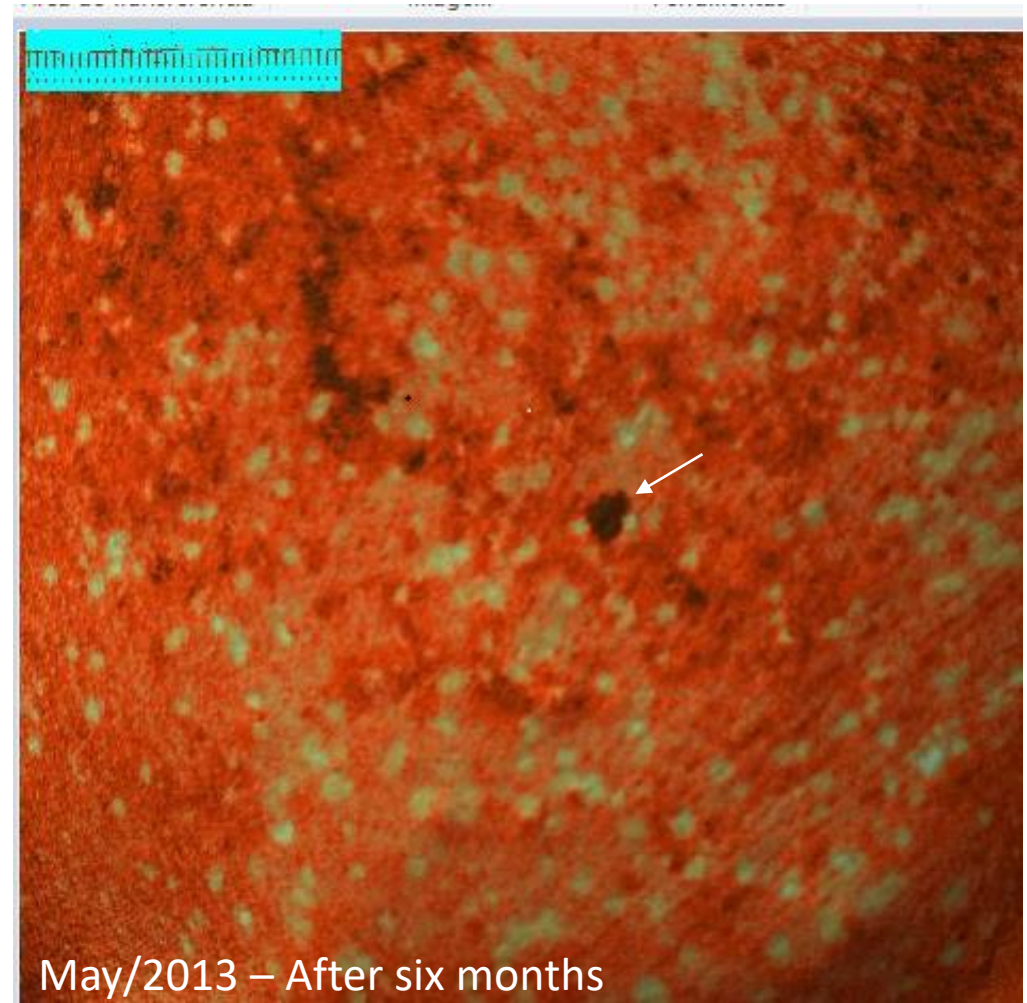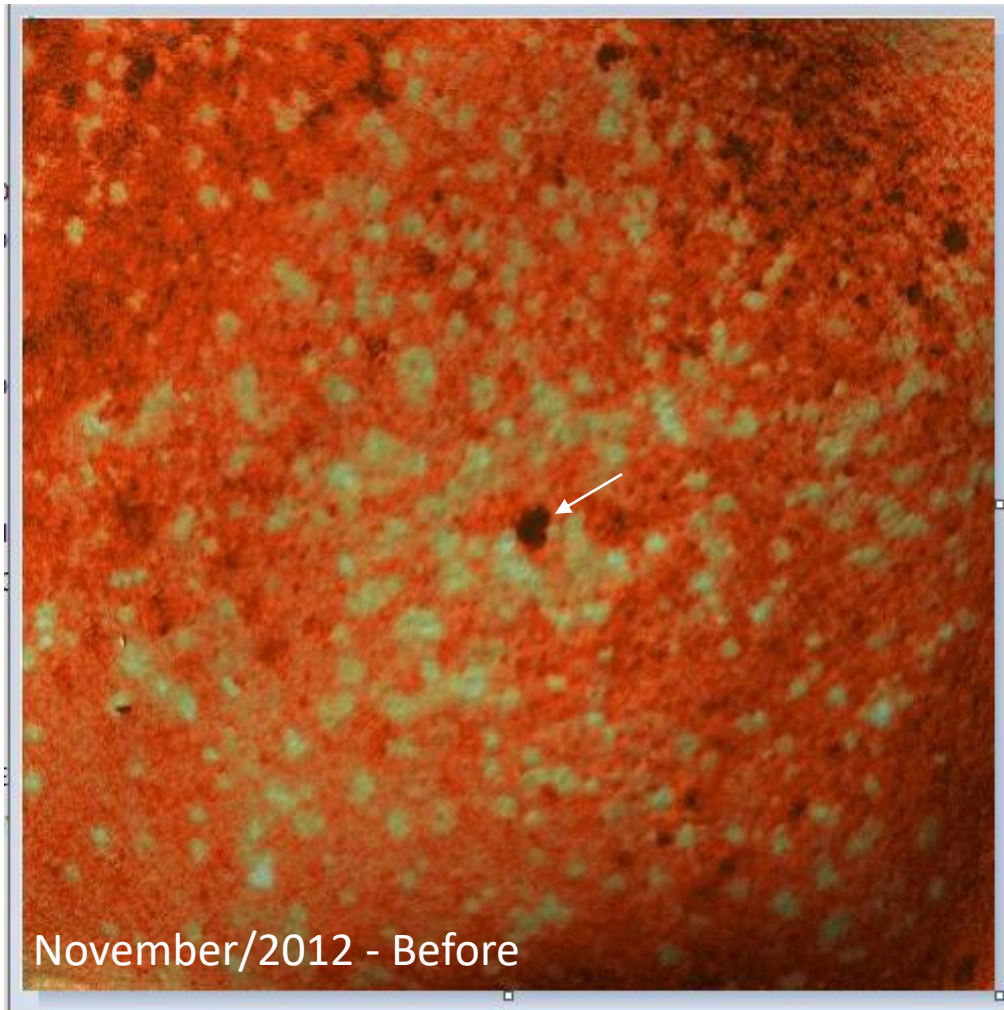


Follow-up in May/2013. Note the slight adjacent hyperpigmentation.
Photos taken with Visia (canfield).



Result after six months. Note the slight hyperpigmentation.
Photos taken with Visia (canfield).





Antera colorimetry. Observe the reduction of achromatic lesions around the nevic lesion
White arrows points to the nevic lesion